

## The Effects of Cerebrovascular and Alzheimer Disease on Patterns of Ventricular Expansion Rate Derived from Serial MRI

C. Studholme<sup>1,2</sup>, V. Cardenas<sup>1,2</sup>, N. Schuff<sup>1,2</sup>, M. Krishnan, H. Chui<sup>3</sup>, M.W. Weiner<sup>1,2</sup>

<sup>1</sup>VA Medical Center, <sup>2</sup>University of California at San Francisco and <sup>3</sup>University of Southern California, Los Angeles

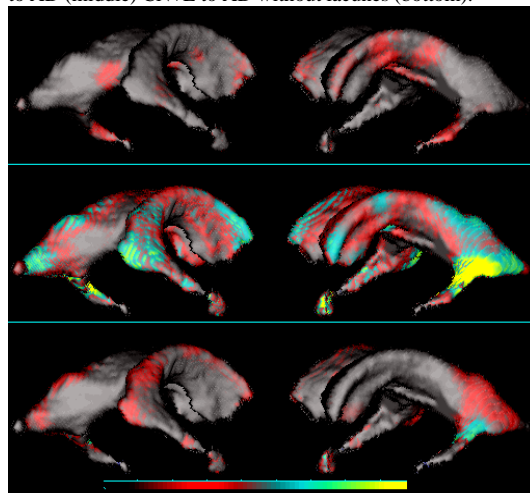
The expansion of the ventricular CSF-white matter boundary over time is of interest in short term serial MRI because of its high contrast and high rate of change. We examined magnitudes and patterns of ventricular expansion rate in cognitively normal elderly without (N=34) and with (N=18) lacunes, and in 18 Alzheimer's patients without lacunes, using high-resolution tensor morphometry. Normal fusion visualization of the tensor field with respect to a reference ventricular surface revealed significant increases in expansion rate associated with both lacunes and Alzheimer's disease. These findings highlight the importance of considering cerebrovascular and Alzheimer's disease as independent pathological processes.

**Objectives:** To examine differences in the common patterns of ventricular expansion over time in three groups: cognitively normal subjects without lacunes, cognitively normal with lacunes and subjects diagnosed with Alzheimer's disease.

**Methods:** 34 Cognitively normal subjects without lacunes (CN: Age=73.5±6.5), 18 subjects with 1 or more lacunes (CN+L: Age=74±7.8) and 18 AD patients without apparent vascular disease on MRI (AD: Age=74.8±6.4) were studied with structural MRI obtained at two time points using a T1-weighted MP-RAGE (TR/TE/TI=10/4/300ms, 1x1x1.5mm resolution) at intervals of between 1 and 3 years. Lacunes were identified as discrete signal hyperintensities >3mm in diameter in proton density MRI. The location of lacunes was thalamic (n=6), basal ganglia (n=6) and white matter (n=6). The paired images for each subject were spatially registered using an entropy driven [1] fine lattice (1.5mm knot spacing Cubic B-Spline) free form deformation [2] to capture local changes in tissue volume over time. Maps of local point-wise volume changes in each subject were then estimated by analytically evaluating the Jacobian of this transformation from the B-Spline transformation. A further transformation between each subject's time point 1 MRI and a common reference control subject MRI (72yo CN female) was estimated using a multi-resolution B-Spline registration with lattice spacings of 14.4, 7.2, 3.6 and 1.8mm. This transformation was then used to spatially normalize each subject's volume change map to the common anatomical coordinate system of the reference MRI. The ventricular region of the single reference MRI anatomy was manually segmented and the statistics of the tensor fields were then visualized with respect to this anatomical boundary using a normal fusion [3] volume visualization algorithm.

**Results:** Figure 1 shows the spatial patterns CSF expansion rate effect size between groups with respect to the reference ventricular surface. This differential expansion rate of the CSF-white matter boundary indicates increased rates of white matter tissue loss in regions normal to the ventricular surface. The presence of lacunes alone in cognitive normal subjects appears associated with an increase in the overall rate of CSF expansion and the rate of adjacent white matter loss. Although the increase in mean rate of expansion is large, the effect size reaches only 0.75, due, possibly to the inherent variability of lacune location. The strongest effects due to the presence of lacunes occur in the rate of expansion of the frontal lateral ventricles and in the ventricular space adjacent to the hippocampus. In contrast, AD increases expansion rate with a relatively large effect over most of the ventricular surface, concentrated most strongly in the posterior temporal horns, which is consistent with the loss of neurons and white matter in the adjacent temporal and parietal lobes. The effect of AD with respect to CN+L indicates that expansion of the frontal lateral ventricle is not specific to AD. Rather, the location of effects that most strongly differentiates

**Figure 1:** Coloured patterns of averaged effect size of point-wise expansion to a depth of 4mm from the reference ventricular surface comparing rate in: CN to CN+L (top), CN to AD (middle) CN+L to AD without lacunes (bottom).



Effect Size: 0.5 | 0.75 | 1.0 | 1.25  
between CN+L and AD groups is CSF expansion in the posterior temporal horn.

**Discussion:** Brain shape analysis from serial MRI can only examine tissue loss indirectly by inferring its location from the shift in boundaries between tissues with MRI contrast. The expansion of ventricular CSF reflects the loss of deep white and gray matter structures adjacent to the ventricle. The use of high-resolution non-rigid registration between subjects MRI allows us to find corresponding regions on the otherwise anatomically featureless surfaces of the ventricles, permitting us to study common local patterns of change not easily identified by human observation across multiple subjects. By studying ventricular expansion separately in AD and cognitively normal subjects with and without lacunes we have identified separate and confounding patterns of shape change associated with these clinical conditions. A surprising finding is that the presence of lacunes, even in cognitively normal subjects, is associated with an increased rate of ventricular expansion. It is not clear whether this reflects the local or distal effects of lacunes or whether lacunes represent surrogate markers for more widespread cerebrovascular disease. Further data acquisition and analysis will allow the influence of lacune location on the pattern of volume change to be examined. In addition, the use of more sophisticated statistical techniques will allow us to model the influence of confounds such as disease stage and age on the patterns of change.

**Acknowledgements:** This work was funded by grants from the Whitaker foundation and NIH grants #AG10897 and #AG12435.

### References:

1. C. Studholme, D. Hill, D. Hawkes, "An Overlap Invariant Entropy Measure of 3D Medical Image Alignment", *Pattern Recognition*, 1999, 32, 71-86.
2. C. Studholme, V. Cardenas, M. Weiner, "Building Whole Brain maps of Atrophy Rate from Multi-Subject Longitudinal Studies Using Free-Form Deformations", *Proc ISMRM 2001*.
3. R. Stokking, "Normal Fusion for 3D integrated visualization of SPECT and MR brain images", *Journal of Nuclear Medicine*, 1997, 38(4): 624-629.